

● *Original Contribution*

CLINICAL USE OF ULTRASOUND TISSUE HARMONIC IMAGING

F. TRANQUART,[†] N. GRENIER,[‡] V. EDER[†] and L. POURCELOT[†]

[†]CHU Bretonneau-37044 Tours, Cedex, France; and [‡]Groupe Hospitalier Pellegrin, 33076, Bordeaux, Cedex, France

(Received 5 February 1999; in final form 9 April 1999)

Abstract—The recent introduction of tissue harmonic imaging could resolve the problems related to ultrasound in technically difficult patients by providing a marked improvement in image quality. Tissue harmonics are generated during the transmit phase of the pulse-echo cycle, that is, while the transmitted pulse propagates through tissue. Tissue harmonic images are formed by utilizing the harmonic signals that are generated by tissue and by filtering out the fundamental echo signals that are generated by the transmitted acoustic energy. To achieve this, two processes could be used; one by using filters for fundamental and harmonic imaging and the second using two simultaneous pulses with a 180° difference in phase. The introduction of harmonics allows increased penetration without a loss of detail, by obtaining a clearer image at depth with significantly less compromise to the image quality caused by the use of lower frequencies. This imaging mode could be used in different organs with a heightening of low-contrast lesions through artefact reduction, as well as by the induced greater intrinsic contrast sensitivity of the harmonic imaging mode. © 1999 World Federation for Ultrasound in Medicine & Biology.

Key Words: Ultrasound, Harmonics.

INTRODUCTION

In recent years, diagnostic ultrasound has greatly improved due to numerous technological developments that enable display of new information. These ultrasound and software improvements typically have a significant impact on the technically satisfactory patient subgroup, as so often demonstrated in commercial literature. The effect on the technically difficult patient subgroup, however, has remained limited.

The second long-standing problem concerns images provided to the clinicians for reporting. Here, the consequences of technically sub-optimal recordings are potentially more serious, leading to uncertainty in diagnosis and/or costly repeat examinations.

The classic solution in examining technically difficult patients is to find a different acoustic window or to use lower-frequency transducers and different control settings that, in some cases, may slightly improve image quality. The other solution is to refer the patient to other imaging modalities, such as nuclear medicine, computerized tomography (CT), or magnetic resonance imaging

(MRI), but with obvious impact on the cost and the expediency of the diagnosis.

The recent introduction of the tissue harmonic imaging modality could resolve these problems by providing a marked improvement in image quality in difficult patients. The observation of harmonics generated by contrast agents as described by Burns (1996) has focused research on acoustic harmonics that has been previously described. Sound waves are the sum of different component frequencies, the fundamental frequency and harmonics. Harmonics are integral multiples of the fundamental (first harmonic). The combination of the fundamental and its harmonics gives the detected signal its characteristics.

BASIC PRINCIPLES OF TISSUE HARMONICS

Harmonics in ultrasound are generated by tissue or by contrast agents. Contrast-agent harmonics are generated by reflections from the injected contrast agent and not from reflections from tissue. The nonlinear properties of microbubbles, which resonate when insonified, produce fundamental and harmonic frequency bands. One of the advantages of harmonic imaging using contrast agents has been to demonstrate the reduction of artefacts induced by these agents.

When no contrast is employed, harmonics are gen-

Address correspondence to: F. Tranquart, INSERM U 316, CHU Bretonneau, 37044 Tours, Cedex 1, France. E-mail: tranquart@med.univ-tours.fr

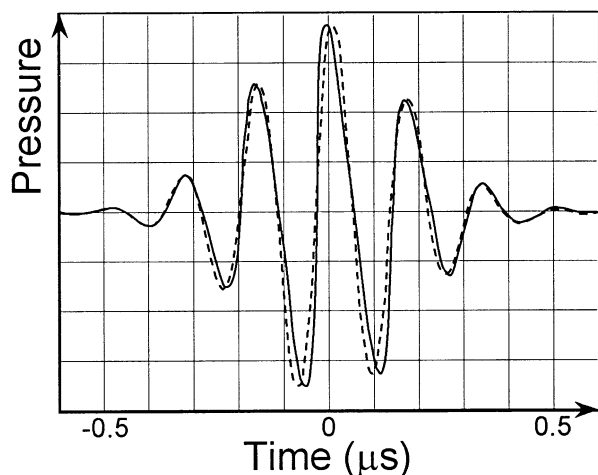


Fig. 1. Distortion of the acoustic pulse during propagation within the tissue. The dotted line represents the pulse at 0 cm and the solid line this pulse at 10 cm.

erated by tissue itself as a result of the distal propagation of the fundamental (transmitted) band. When a transducer sends out a band of frequencies that have a certain characteristic center frequency, for example 2 MHz, the returned energy will be in two or more frequency bands or spectra. The first corresponds to the transmitted fundamental band centered at 2 MHz and the second is the second harmonic band centered at 4 MHz. The fundamental band consists of echoes produced by tissue interfaces and inhomogeneities, whereas the harmonic band is generated by the tissue itself.

Tissue harmonics are generated during the transmit phase of the pulse-echo cycle; that is, while the transmitted pulse propagates through tissue. At any instant, the peaks travel slightly faster than the troughs because of different velocity of ultrasound propagation in compressed tissue as opposed to relaxed tissue (Fig. 1). This behavior generates an infinitesimal amount of harmonics (Fig. 2) (Law et al. 1985; Muir and Cartensen 1997). Although the amount of harmonics that tissue generates at any given instant remains infinitesimal, the cumulative harmonic intensity increases as the pulse propagates through tissue (Sehgal et al. 1986; Starritt et al. 1986; Ward et al. 1997).

At the skin level, tissue harmonics are virtually zero; however, their intensity increases with depth up to the point where tissue attenuation overcomes this build-up and causes them to decrease. This is radically different from the intensity of the fundamental frequencies, which are attenuated linearly with depth. At all depths, however, tissue-harmonic intensity remains lower than that of the fundamental.

It is important to point out that tissue harmonic imaging allows the use of lower frequencies for trans-

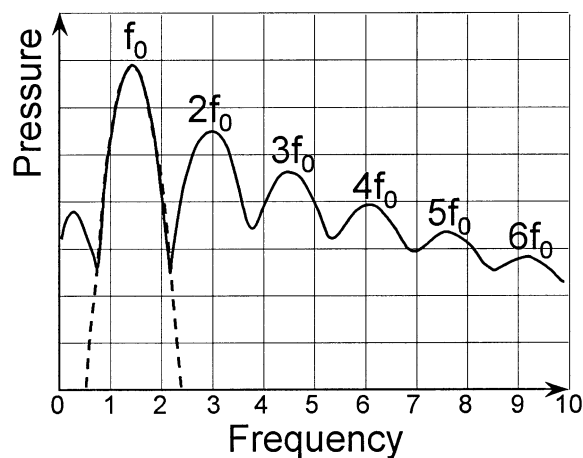


Fig. 2. Frequency spectrum of the received signal. The dotted line represents the single fundamental band frequency obtained at 0 cm and the solid line represents the multiple harmonics obtained at 10 cm.

mission. Additionally, this mode benefits from a relative autofocusing because the harmonics are generated in the center of the beam where the acoustic pressure is maximum. This mode of imaging is, however, only possible using very wide band transducers.

THEORETICAL ADVANTAGES

First, the signal-to-noise and contrast-to-noise ratios are improved. The primary cause of image noise and clutter is the composition of the body wall. Specifically, the amounts of fat, skin layer thickness and hydration level are some of the principal causes of ultrasound (US) beam distortion and scattering. In addition, lateral and slice thickness sidelobes (Christopher 1997; Rubin et al. 1998), as well as reverberation artefacts, also contribute to generate image clutter. This distorted and scattered energy is much weaker than the transmitted energy and, therefore, generates much weaker harmonics. As a result, tissue harmonic image contains minimal noise and clutter compared to fundamental imaging.

Second, the spatial resolution is improved. The narrowing of the width of the US beam improves the lateral resolution (Starritt et al. 1986). The decrease of the wavelength of the return harmonic signal compared to the fundamental improves the axial resolution.

Third, even though the penetration in harmonic mode remains lower than when using the fundamental mode because of the attenuation, the visualization of deep structures is frequently improved. The use of tissue harmonics generated from even lower fundamental frequencies (1 MHz) could further improve the visualization of tissue at depth.

IMAGE RECONSTRUCTION WITH TISSUE HARMONIC IMAGING

Tissue harmonic images are formed by utilising the harmonic signals that are generated by tissue and by filtering out the fundamental echo signals that are generated by the transmitted acoustic energy (Freiherr 1998).

Transducers transmit an acoustic pulse that contains a broad band of frequencies. On receive, multiple bands of frequencies are present; the fundamental or transmitted band and multiple harmonic bands that are generated by tissue. Unless the transmitted fundamental band is carefully shaped and controlled, the fundamental and harmonic bands will overlap, resulting in the corruption of the harmonic band by the higher intensity fundamental. This will lead to poor tissue harmonic image quality because noise and clutter from the fundamental signal will be present in the harmonic image.

To obtain the best performance from harmonic imaging, it is essential that no harmonic energy is transmitted in the fundamental band (*i.e.*, the fundamental frequency band must not include any harmonic frequency component in transmit). Therefore, the harmonic component on receive is generated purely from native tissue, not from any component of the incident beam.

Two methods are now available for harmonic imaging: the first one based on filtering of the fundamental component of the receive signal and the second one based on pulse inversion sequence:

1. In the first method, a receive filter is used to filter out this pure tissue harmonic signal, from which the image can then be reconstructed (Fig. 3). This is the first condition that assures us that the harmonic signal is not contributed by any portion of the fundamental frequency band. In addition, the receive filter must be matched to the harmonic band, wholly excluding the

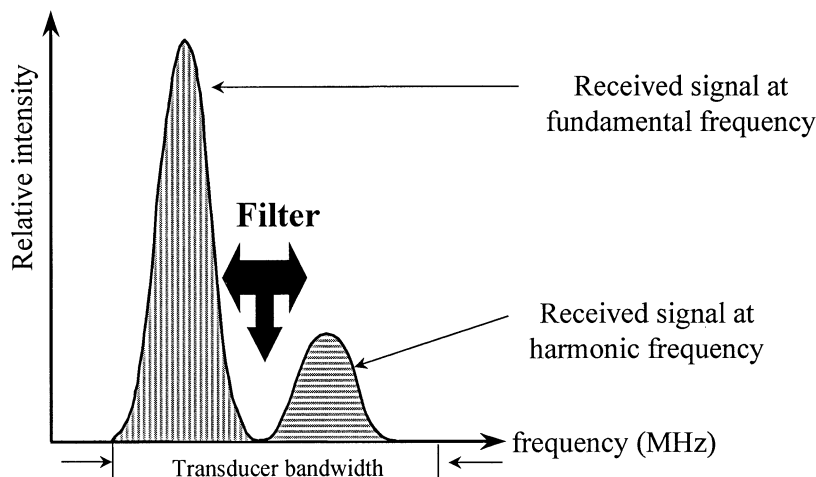


Fig. 3. Relative intensity of the two received signals at fundamental and 2nd harmonic frequency. These two frequencies have to be within the transducer bandwidth. The presence of a filter allows separation of these two frequencies.

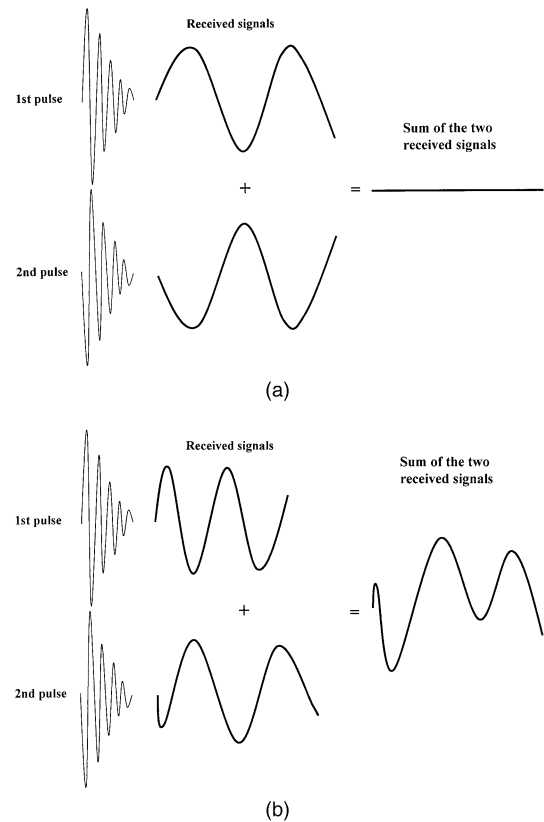


Fig. 4. Phase inversion method. This uses two simultaneous pulses that differ from 180° in phase. (A) Due to linear properties of tissue, the two received signals will cancel in the sum signal. (B) Due to nonlinear properties of tissue, the two received signals will not cancel in the sum signal.

fundamental frequency band. This is the second condition that assures us that the fundamental band is totally filtered out and, thus, prevented from corrupting the harmonic signal. This allows selection of only

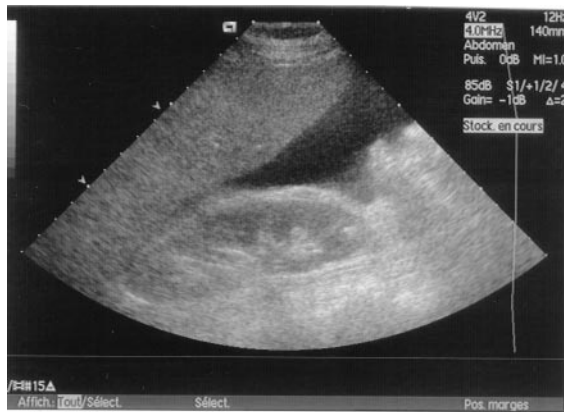

Fig. 5. Abdominal sonography demonstrating a marked ascites with fundamental mode (top) and harmonic imaging (bottom). The second appears clearer than the first.

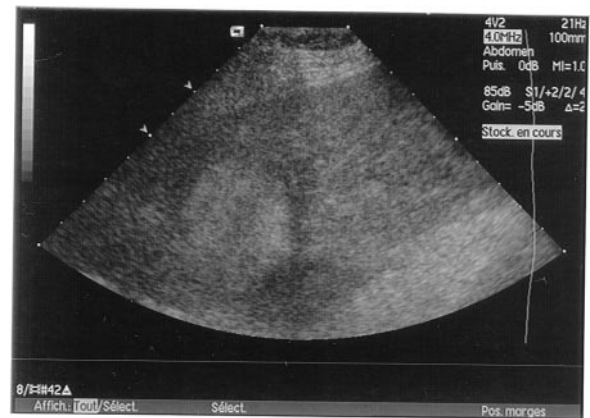

Fig. 6. Liver metastasis with fundamental mode (top) and harmonic imaging (bottom). The second demonstrates a higher contrast in the perilesion halo and gives more precise information on the posterior image of ascites.

the tissue harmonic frequencies for image reconstruction.

2. In the second method, two simultaneous wideband pulses that differ from phase are transmitted and the two received signals are summed; if these transmit pulses differ from 180° in phase, the received signals from linear media have the same amplitude, but a 180° phase difference. The two signals will cancel in the sum signal. In contrast, in nonlinear media, the two received signals are not identical in amplitude and consequently will not cancel in the sum signal (Fig. 4). The advantage of this technique is the high level of signal intensity obtained after the sum of both received signals, but the drawback is a decrease of the temporal resolution related to the double pulse and longer signal processing.

CLINICAL APPLICATIONS

In our preliminary experience, tissue harmonic imaging provided such a significant improvement in quality

of B-mode images that we have modified our routine practice of US examinations.

The minimal noise and clutter in harmonic mode substantially reduces artefacts in liquid cavities, which appear much cleaner and darker on images. This increase in contrast resolution can lead to more confident assessment of abdominal and pelvic masses, particularly in obese patients, differentiating hypoechoic solid masses and cystic lesions. This is often the case in the kidney and the ovaries and, sometimes, in the liver. This enhancement of contrast between echogenic solid and anechoic liquid components has several advantages. In the kidney, where classification of the lesions according to Bosniak's grades has a significant clinical impact, the better conspicuity of septas, calcifications, or nodules on harmonic images improves the confidence in gradation. Evaluation of the gallbladder wall and content and of the biliary tree can also be improved with clearer differentiation of gallbladder sludge from artefacts (Fig. 5), and detection of stones. Images of the lumen of vessels

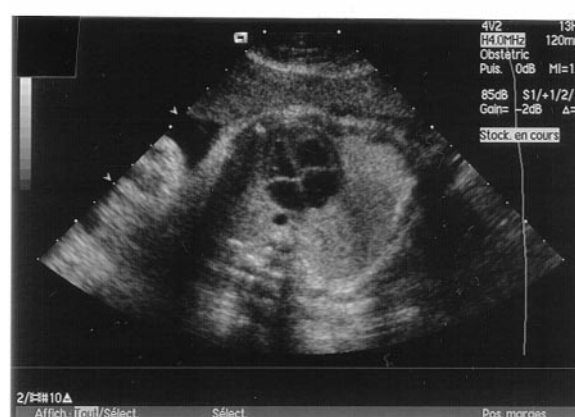
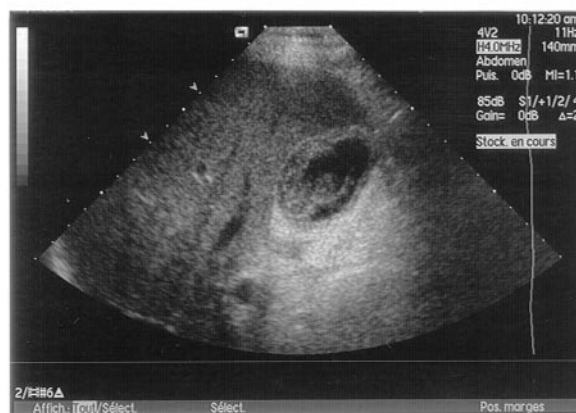
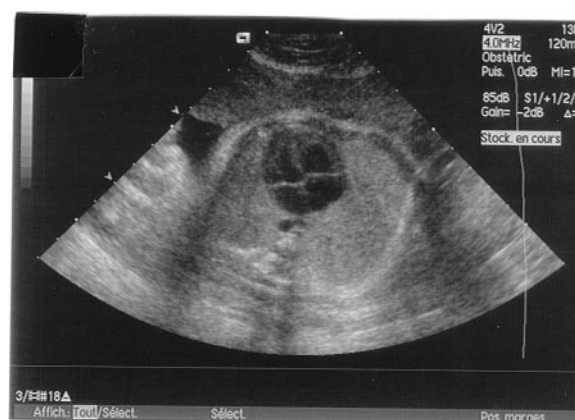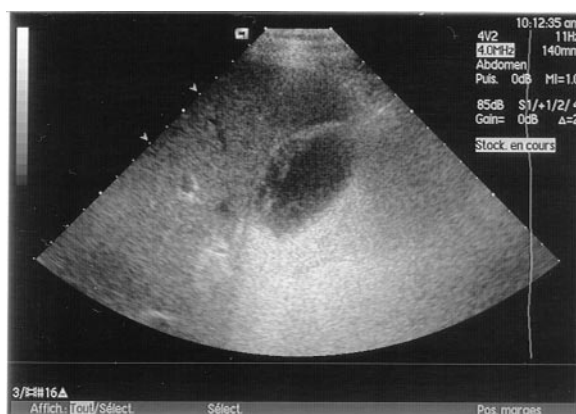Fig. 7. Chronic cholecystitis with fundamental mode (top) and harmonic imaging (bottom). The gallbladder wall and content was precisely studied using harmonic imaging.

Fig. 8. Four-chamber heart in a 35-week-old fetus with fundamental mode (top) and harmonic imaging (bottom). The use of harmonic mode increases the clarity of the image.

appear also with less reverberation artifacts and with a darker lumen on harmonic images. For example, the calf veins are easier to identify within the muscles when using harmonic mode.

The improvement of low-contrast resolution can lead to a better analysis of tissue parenchyma and a better detection of lesions. The pancreatic area is sometimes difficult with a poor contrast between fat and gland and, within the gland, between healthy parenchyma and tumors. A recent study showed that, for the pancreas, harmonic sonography was significantly better than conventional sonography at 2.5 and 4 MHz for penetration, detail and overall image quality (Shapiro *et al.* 1998). Visualization of the pancreatic duct and the common bile duct was also improved. Detection of carcinomas of the pancreatic head should be easier.

The detection of focal liver lesions is often complicated by the presence of fatty infiltration and/or cirrhosis in the liver and abdominal wall reverberation or small intercostal spaces. Harmonic imaging mode can increase the liver-lesion contrast, as well as the visualization of

perilesional halos, leading to improved detection of hepatic lesions (Figs. 6 and 7).

In obstetric imaging, where maternal large body habitus may compromise visualization, imaging in harmonic mode provides clearer depiction of fetal anatomy. This is particularly useful in the depiction of heart architecture and brain anatomy (Figs. 8 and 9). In gynecology, the contrast improvement could lessen the requirement for transvaginal imaging in the detection of subtle uterine processes (Fig. 10).

Sound penetration is often the limiting factor in image quality, and the harmonic imaging mode helps improve the visualization of deep structures. In the past, the use of lower frequencies has been the most commonly applied means of attaining adequate penetration, despite the loss of image detail. The introduction of harmonics could alleviate this problem by obtaining a clearer image at depth with significantly less compromise to the image quality caused by the use of lower frequencies.

In summary, the images obtained in harmonic mode

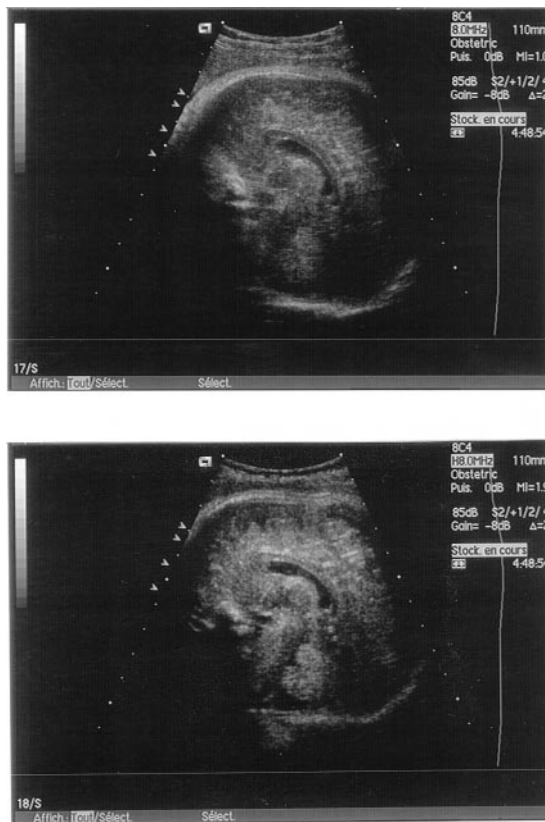

Fig. 9. Sagittal view of the brain from a 32-week-old fetus with fundamental mode (top) and harmonic imaging (bottom) at high frequency. The use of harmonic mode gives more precise detail of the corpus callosum and vermix.

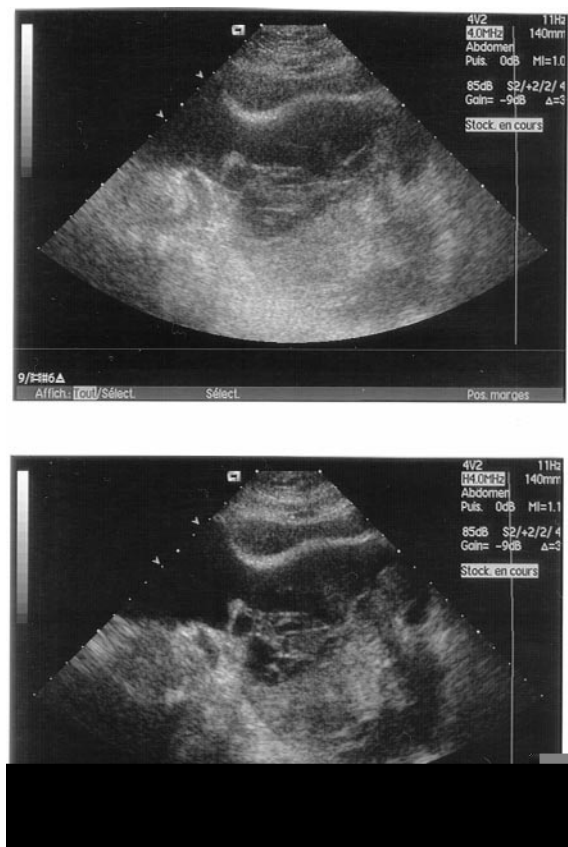


Fig. 10. Ovarian cancer with fundamental mode (top) and harmonic imaging (bottom). The harmonic method gives more precise details on the deep structures, as well as on the differentiation between tissue and cystic component.

reconstructed from signals that are generated by tissue are typically characterized by a reduction in artefacts generated by the body wall, a suppression of sidelobe clutter levels (Christopher 1997; Rubin et al. 1998) and an increased contrast resolution due to reduction in noise levels. This can lead to greater detection and more confident assessment of the internal architecture of lesions. Visualization of low-contrast lesions may be heightened through artefact reduction, as well as by the induced greater intrinsic contrast sensitivity of the harmonic imaging mode. There may, thus, be a significant impact on the interpretation of the images by the clinicians and, hence, on the acceptance of ultrasonography as a valuable method of diagnosis. In the near future, this mode may be essential in all ultrasound machines.

Acknowledgements—The authors thank Tom Jedzrewicz for his help in preparing this manuscript.

REFERENCES

Burns PN. Harmonic imaging with ultrasound contrast agents. *Clin Radiol* 1996;51:50–55.

- Christopher T. Finite amplitude distortion-based inhomogeneous pulse echo ultrasonic imaging. *IEEE Trans Ultrason Ferroelec Freq Control* 1997;44:125–139.
- Freiherr G. Harmonic imaging: what it is, how it works. *Diagnostic Imaging Europe* June 1998;HU6–HU7.
- Law WK, Frizzell LA, Dunn F. Determination of the non-linearity parameter B/A of biological media. *Ultrasound Med Biol* 1985;11:307–318.
- Muir TG, Cartensen EL. Prediction of nonlinear acoustic effects at biomedical frequencies and intensities. *Ultrasound Med Biol* 1997;6:345–357.
- Rubin DN, Yazbek N, Homa D. Why does tissue harmonic imaging improve image quality: a quantitative examination demonstrating side-lobe suppression. (Abstr.) *J Am Coll Cardiol* 1998;32:127A.
- Sehgal CM, Brown GM, Bahn RC, Greenleaf JF. Measurement and use of acoustic nonlinearity and sound speed to estimate composition of excised livers. *Ultrasound Med Biol* 1986;12:865–874.
- Shapiro RS, Wagreich J, Parsons RB, Stancato-Pasik A, Yeh HC, Lao R. Tissue harmonic imaging sonography: evaluation of image quality compared with conventional sonography. *AJR* 1998;171:1203–1206.
- Starritt HC, Duck FA, Hawkins AJ, Humphrey VF. The development of harmonic distortion in pulsed finite-amplitude ultrasound passing through liver. *Phys Med Biol* 1986;31:1401–1409.
- Ward B, Baker AC, Humphrey VF. Nonlinear propagation applied to the improvement of resolution in diagnostic medical ultrasound. *J Acoust Soc Am* 1997;101:143–154.